

# Arthritis induced by dupilumab treatment: A case report and literature review

Ceyhun Bıçlıoğlu, Emir Onağ, Özgür Akgül

Department of Physical Medicine and Rehabilitation, Division of Rheumatology,  
Celal Bayar University, Manisa, Turkey

## ABSTRACT

Dupilumab is a human monoclonal IgG4 antibody targeting the interleukin-4 receptor alpha chain (IL-4R $\alpha$ ). It effectively inhibits the signaling pathways of both interleukin-4 (IL-4) and interleukin-13 (IL-13) and has been extensively employed in managing conditions such as atopic dermatitis, asthma, allergic rhinitis, and other allergic disorders. Despite numerous studies affirming its safety profile, suppression of IL-4 and IL-13 has been linked to an increased dominance of interleukin-17 (IL-17), which can lead to adverse effects resembling those seen in psoriatic arthritis and spondyloarthritis-like symptoms. Through a case study of a patient receiving dupilumab for prurigo nodularis, this paper seeks to shed light on the potential inflammatory disease-like side effects associated with this treatment. Specifically, we explore manifestations such as enthesitis/arthritis, psoriasis, uveitis, inflammatory bowel disease, lupus erythematosus, and vasculitis, urging vigilance among rheumatologists and dermatologists.

**Keywords:** dupilumab, IL-4, IL-13, IL-17, side effects, inflammatory disease-like side effects, safety

## INTRODUCTION

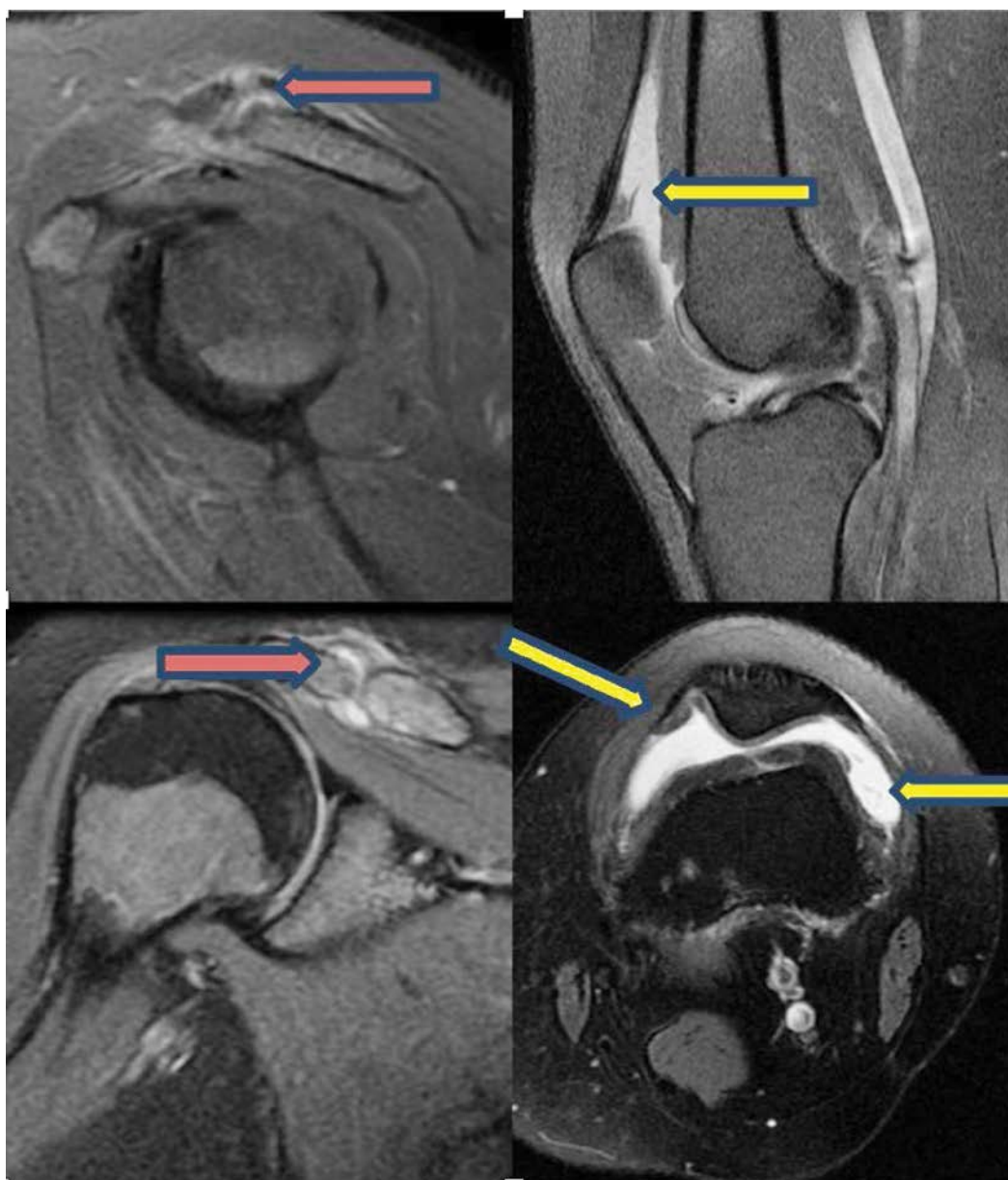
Dupilumab is a human monoclonal IgG4 antibody that targets the interleukin-4 receptor alpha chain (IL-4R $\alpha$ ). It inhibits the signaling of both interleukin-4 (IL-4) and interleukin-13 (IL-13) and has been successfully used in the treatment of atopic dermatitis, asthma, and other allergic diseases. In recent years, it has also gained indications for the treatment of several other conditions. While dupilumab is generally well-tolerated, recent publications have reported various adverse events. The most frequently reported adverse events include nasopharyngitis, upper respiratory tract infections, headaches, injection site reactions, and conjunctivitis [1].

In addition, there have been reports in recent years of side effects that mimic rheumatologic diseases [2]. In our clinic, we examined a case, along with a review of case series in the literature, that reported rheumatologic disease-mimicking side effects associated with the use of dupilumab.

## CASE PRESENTATION

A 39-year-old female patient started treatment with dupilumab four months ago for prurigo nodularis and presented to our clinic ten days ago with recent onset of left knee pain. The patient described the pain as inflammatory and reported morning stiffness lasting for one hour. Apart from a recent episode of acute left shoulder pain, which was relieved following an intra-articular corticosteroid injection one month prior, her rheumatologic inquiry was otherwise unremarkable.

Physical examination revealed minimal restriction in internal rotation of the left shoulder, swelling in the left knee, slight warmth, and limited mobility. Laboratory findings showed an elevation in acute phase reactants, but no other pathological findings were noted. Imaging studies identified arthritis in both the knee and acromioclavicular joint (Figure 1). MRI scans displayed arthritis in both the acromioclavicular and knee joints (Figure 1). These images highlight the presence of inflammatory changes typical of arthritis, which are pertinent findings in the context



**FIGURE 1.** MRI imaging of the knee and shoulder  
*Red arrows indicate acromioclavicular joint arthritis*  
*Yellow arrows indicate knee joint arthritis*

of adverse reactions potentially linked to dupilumab treatment.

The patient underwent ultrasound-guided aspiration of the knee, followed by a corticosteroid injection, and was started on NSAID (Non-Steroidal Anti-Inflammatory Drug) therapy for further management. She was kept under observation with continuing dupilumab treatment. At the two-month follow-up, there was no recurrence of arthritis.

## METHOD

We conducted a comprehensive PubMed search for articles published up to March 2024, using keywords such as dupilumab, psoriasis, psoriatic arthritis, arthritis, enthesitis, sacroiliitis, uveitis, conjunctivitis, inflammatory bowel disease, vasculitis, lupus

erythematosis, spondylitis, dactylitis, and side effects. This search encompassed clinical trials, observational studies, meta-analyses, and case reports. The findings are summarized in the table below.

In addition to examining the side effects, the search also included studies that discussed the drug's indications, safety, and other potential adverse effects, providing a comprehensive evaluation of dupilumab's clinical profile.

## RESULTS

The number of cases in the studies, along with age, gender, diagnosis, drug side effects, duration of drug use, diagnostic methods, treatment, and drug discontinuation, are shown in Table 2 (NA: no answer).

TABLE 1. General information

	Psoriasis	Arthritis	Lupus	Vasculitis	Spondyloarthritis	Uveitis	IBD	Total
<b>Number of patients</b>	78	15	3	14	1	3	2	116
<b>Average age</b>	40	48	34	54	44	43	18	40.142
<b>Average symptom duration(weeks)</b>	25	20	48	12	104	58	14	40.142
<b>Sex</b>								
<b>Male</b>	49(%62,82)	8(%53,33)	0(%0,00)	4(%28,57)	1(%100)	0(%0,00)	1(%50,00)	9
<b>Female</b>	29(37,18)	7(%46,66)	3(%100)	10(%71,43)	0(%0,00)	3(%100)	1(%50,00)	7.57

\*The total number of patients and average symptom duration were calculated across all conditions. The percentage values for gender distribution within each condition are provided. The average age and symptom duration values are presented in years and weeks, respectively.

TABLE 2. Case reports of psoriasis developed due to dupilumab

Ref.	Case	Sex	Age	Patient history	Side effect	Duration (weeks)	Side effect diagnosis	Management	Dupilumab interruption
(1)	1	male	16	atopic dermatitis	psoriasis	4	Inspection	topical steroid cyclosporine	yes
(1)	2	male	25	atopic dermatitis	psoriasis	4	Inspection	methotrexate	yes
(1)	3	male	25	atopic dermatitis	psoriasis	8	Inspection	ustekinumab infliximab steroid	yes
(1)	4	male	55	atopic dermatitis	psoriasis	8	Biopsy	topical steroid	no
(1)	5	female	54	atopic dermatitis	psoriasis	16	Biopsy	NA	yes
(1)	6	female	49	atopic dermatitis	psoriasis	72	Inspection	topical steroid	no
(1)	7	female	59	atopic dermatitis	psoriasis	4	Biopsy	topical steroid	yes
(1)	8	female	40	atopic dermatitis	psoriasis	14	Biopsy	topical calcipotriol topical steroid	no
(1)	9	male	73	atopic dermatitis	psoriasis	4	NA	NA	NA
(1)	10	male	80	atopic dermatitis	psoriasis	10	Biopsy	NB-UVB	yes
(1)	11	male	42	atopic dermatitis	psoriasis	12	Biopsy	topical calcipotriol topical steroid	yes
(1)	12	female	36	atopic dermatitis	psoriasis	20	Biopsy	topical steroid	yes
(1)	13	male	59	atopic dermatitis	psoriasis	4	Biopsy	NA	yes
(1)	14	male	60	asthma	psoriasis	14	Biopsy	topical steroid	yes
(1)	15	female	32	NA	psoriasis	4	Inspection	topical steroid	no
(1)	16	male	67	NA	psoriasis	8	Inspection	topical steroid	no
(1)	17	female	57	NA	psoriasis	36	Inspection	topical steroid	no
(1)	18	female	61	atopic dermatitis	psoriasis	4	Inspection	topical steroid	no
(1)	19	female	56	atopic dermatitis	psoriasis	8	Biopsy	topical calcipotriol topical steroid	no
(1)	20	male	39	alopesi areata	psoriasis	4	Inspection	topical steroid	no
(1)	21	male	40	atopic dermatitis	psoriasis	6	Inspection	topical steroid oral steroid cyclosporine	yes
(1)	22	male	72	atopic dermatitis	psoriasis	16	Inspection	topical steroid	no
(1)	23	male	24	atopic dermatitis	psoriasis	6	Inspection	topical steroid cyclosporine	yes
(1)	24	male	92	atopic dermatitis	psoriasis	32	Biopsy	Mycophenolate mofetil	no
(1)	25	female	45	atopic dermatitis	psoriasis	48	Inspection	topical steroid	no
(1)	26	male	22	atopic dermatitis	psoriasis	20	Biopsy	topical calcipotriol topical steroid	NA
(1)	27	female	68	NA	psoriasis	4	Biopsy	oral steroid	yes
(1)	28	male	34	atopic dermatitis	psoriasis	120	Biopsy	topical steroid tacrolimus ointment %0,1 delgocitinib ointment	no

Ref.	Case	Sex	Age	Patient history	Side effect	Duration (weeks )	Side effect diagnosis	Management	Dupilumab interruption
(1)	29	male	23	atopic dermatitis	psoriasis	72	Biopsy	topical steroid tacrolimus ointment %0,1 delgocitinib ointment	no
(1)	30	male	24	atopic dermatitis	psoriasis	8	Biopsy	topical steroid	no
(1)	31	male	46	atopic dermatitis	psoriasis	96	Biopsy	topical steroid tacrolimus ointment %0,1	no
(1)	32	female	28	atopic dermatitis alopecia totalis	psoriasis	20	NA	topical steroid	yes
(1)	33	female	25	atopic dermatitis	psoriasis	8	NA	topical hormonal cream	yes
(1)	34	male	22	atopic dermatitis	psoriasis	16	Biopsy	topical calcipotriol topical steroid	yes
(1)	35	male	23	atopic dermatitis	psoriasis	8	Biopsy	topical steroid cyclosporine	yes
(1)	36	female	58	atopic dermatitis	psoriasis	22	Biopsy	upadacitinib	yes
(1)	37	female	51	atopic dermatitis	psoriasis	8	Biopsy	oral steroid	yes
(1)	38	male	36	atopic dermatitis	psoriasis	100	NA	topical calcipotriol topical steroid	no
(1)	39	female	36	atopic dermatitis	psoriasis	100	NA	topical calcipotriol topical steroid	no
(1)	40	female	36	atopic dermatitis	psoriasis	100	NA	topical calcipotriol topical steroid	no
(1)	41	female	36	atopic dermatitis	psoriasis	100	NA	topical calcipotriol topical steroid	no
(1)	42	male	61	atopic dermatitis	psoriasis	42	Biopsy	topical steroid	yes
(1)	43	male	61	atopic dermatitis	psoriasis	42	Inspection	topical steroid	yes
(1)	44	male	61	atopic dermatitis	psoriasis	42	Inspection	topical steroid cyclosporine	no
(1)	45	female	61	atopic dermatitis	psoriasis	42	Inspection	cyclosporine	no
(1)	46	female	20	atopic dermatitis	psoriasis	4	Biopsy	topical steroid baricitinib	yes
(1)	47	male	50	atopic dermatitis	psoriasis	16	Biopsy	topical steroid methotrexate	yes
(1)	48	female	25	atopic dermatitis	psoriasis	2	Biopsy	upadacitinib	yes
(1)	49	male	47	atopic dermatitis	psoriasis	26	Biopsy	upadacitinib	yes
(1)	50	male	39	atopic dermatitis	psoriasis	40	Biopsy	NA	no
(1)	51	male	84	atopic dermatitis	psoriasis	6	Biopsy	methotrexate	yes
(1)	52	male	65	atopic dermatitis	psoriasis	10	Biopsy	methotrexate	yes
(1)	53	female	50	chronic rhinosinusitis	psoriasis	4	NA	topical steroid	yes
(1)	54	male	30	chronic rhinosinusitis	psoriasis	4	Biopsy	topical calcipotriol topical steroid	no
(1)	55	female	48	chronic rhinosinusitis	psoriasis	14	Biopsy	topical calcipotriol topical steroid omalizumab	yes
(1)	56	male	36	chronic rhinosinusitis	psoriasis	18	Inspection	NA	no
(1)	57	male	82	chronic rhinosinusitis	psoriasis	24	Biopsy	topical steroid	no
(1)	58	male	25	atopic dermatitis	psoriasis	32	Inspection	topical and systemic steroid cyclosporine	yes
(1)	59	male	4	atopic dermatitis	psoriasis	44	Inspection	topical steroid ustekinumab	yes
(1)	60	female	14	atopic dermatitis	psoriasis	32	Inspection	topical steroid	no
(1)	61	female	12	atopic dermatitis	psoriasis	40	Inspection	topical steroid	no
(1)	62	male	16	atopic dermatitis	psoriasis	28	Inspection	topical steroid	no
(1)	63	male	17	atopic dermatitis	psoriasis	8	Biopsy	topical steroid tacrolimus ointment %0,1	no

Ref.	Case	Sex	Age	Patient history	Side effect	Duration (weeks)	Side effect diagnosis	Management	Dupilumab interruption
(1)	64	male	17	atopic dermatitis	psoriasis	20	Biopsy	baricitinib	yes
(1)	65	male	17	atopic dermatitis	psoriasis	20	Biopsy	baricitinib	yes
(1)	66	male	9	atopic dermatitis	psoriasis	12	Biopsy	topical steroid	NA
(1)	67	male	16	atopic dermatitis	psoriasis	4	Inspection	topical steroid cyclosporine	yes
(1)	68	female	50	atopic dermatitis	psoriasis	8	Biopsy	topical steroid methotrexate	yes
(1)	69	male	35	atopic dermatitis	psoriasis	20	Biopsy	NA	NA
(1)	70	male	18	atopic dermatitis	psoriasis	28	NA	topical steroid	no
(1)	71	female	18	atopic dermatitis	psoriasis	24	NA	topical steroid pimecrolimus %1 cream	no
(1)	72	male	25	atopic dermatitis	psoriasis	4	Inspection	topical steroid methotrexate	yes
(1)	73	female	9	atopic dermatitis	psoriasis	12	Inspection	topical steroid	no
(1)	74	male	13	atopic dermatitis	psoriasis	NA	Biopsy	NA	yes
(1)	75	male	63	atopic dermatitis	psoriasis	NA	Biopsy	nb-UVB	yes
(1)	76	male	70	atopic dermatitis	psoriasis	NA	Biopsy	nb-UVB	yes
(1)	77	male	50	atopic dermatitis	psoriasis	NA	Biopsy	nb-UVB	yes
(1)	78	female	50	prurigo nodularis	psoriasis	48	Inspection	topical calcipotriol topical steroid	yes

#### Case reports of arthritis developed due to dupilumab

Ref.	Case	Sex	Age	Patient history	Side effect	Duration (weeks)	Side effect diagnosis	Management	Dupilumab interruption
(3)	1	male	32	atopic dermatitis	arthritis	8	clinical	no	yes
(3)	2	male	64	atopic dermatitis	arthritis	1	clinical	steroid methotrexate	yes
(3)	3	female	60	atopic dermatitis	arthritis	76	clinical	steroid, ibuprofen acetaminophen	yes
[6]	4	female	68	atopic dermatitis	arthritis+enthesitis	6	ultrasound	NA	yes
(4)	5	male	40	atopic dermatitis	arthritis+enthesitis	16	ultrasound	NA	yes
(4)	6	male	48	atopic dermatitis	arthritis+enthesitis	6	ultrasound+mri	celecoxib	no
(3)	7	female	38	atopic dermatitis	arthritis	1	clinical+ radiography	celecoxib steroid	yes
(3)	8	male	47	atopic dermatitis allergic asthma rhinosinusitis	arthritis	4	ultrasound	NA	NA
(3)	9	female	44	atopic dermatitis	arthritis+enthesitis	10	ultrasound	celecoxib	no
(3)	10	male	54	atopic dermatitis	enthesitis	8	ultrasound	celecoxib methotrexate	no
(3)	11	female	18	atopic dermatitis allergic asthma	arthritis	2	ultrasound+mri	diclofenac intra-articular steroid	no
(5)	12	male	49	atopic dermatitis	arthritis+enthesitis	20	ultrasound	baricitinib	Yes
(6)	13	female	72	atopic dermatitis	arthritis	96	radiography	acetaminophen adalimumab	no
(6)	14	male	59	atopic dermatitis	arthritis	32	clinical	hydroxychloroquine steroid	no
	15	female	39	prurigo nodularis	arthritis	17	ultrasound+mri	intra-articular steroid, acemetacin	no

#### Case reports of lupus developed due to dupilumab

Ref.	Case	Sex	Age	Patient history	Side effect	Duration (weeks)	Side effect diagnosis	Management	Dupilumab interruption
(7)	1	female	27	atopic dermatitis	lupus	2	laboratory, imaging	hydroxychloroquine, NSAID	no
(8)	2	female	54	atopic dermatitis	lupus	72	laboratory, biopsy	hydroxychloroquine local steroid	no

Ref.	Case	Sex	Age	Patient history	Side effect	Duration (weeks)	Side effect diagnosis	Management	Dupilumab interruption
(9)	3	female	21	atopic dermatitis	lupus	60	laboratory	systemic corticosteroid hydroxychloroquine belimumab	yes

**Case reports of vasculitis developed due to dupilumab**

Ref.	Case	Sex	Age	Patient history	Side effect	Duration (weeks)	Side effect diagnosis	Management	Dupilumab interruption
(10)	1	female	61	eosinophilic asthma, rhinosinusitis	eosinophilic vasculitis	32	laboratory, biopsy	benralizumab	no
(11)	2	male	49	chronic sinusitis, asthma	pleural effusion	6	hypereosinophilia, biopsy, imaging	benralizumab corticosteroid	yes
(11)	3	female	66	asthma	cutaneous vasculitis cranial embolism	6	hypereosinophilia, biopsy, imaging	corticosteroid	yes
(12)	4	male	50	asthma, eosinophilic rhinitis	egpa	20	2022 eular	corticosteroid	yes
(13)	5	male	58	chronic sinusitis, asthma	egpa	2	2022 eular	corticosteroid	yes
(14)	6	female	67	asthma, chronic sinusitis	Periaortitis egpa	40	2022 eular	corticosteroid mepolizumab	yes
(15)	7	female	68	atopic dermatitis	leukocytoclastic vasculitis	2	biopsy	corticosteroid	yes
(16)	8	female	63	asthma, eosinophilic otitis media	egpa	4	2022 eular	corticosteroid azathioprine	yes
(17)	9	female	59	asthma, chronic sinusitis	egpa	1	asthma, eosinophilia coronary and cranial involvement	corticosteroid benralizumab	yes
(17)	10	male	35	asthma	egpa	6	sinonasal symptom, asthma, eosinophilia	corticosteroid reslizumab	yes
(17)	11	female	47	asthma	egpa	NA	sinonasal symptom, asthma, eosinophilia	corticosteroid benralizumab	yes
(17)	12	female	63	asthma	egpa	16	cranial involvement, eosinophilia, eosinophilia	corticosteroid mepolizumab	yes
(16)	13	female	25	asthma, chronic sinusitis	egpa	2	asthma, eosinophilia	corticosteroid	yes
(16)	14	female	57	asthma, chronic sinusitis	egpa	8	Arthralgia, eosinophilia, asthma	corticosteroid	yes

**Case reports of SPA developed due to dupilumab**

Ref.	Case	Sex	Age	Patient history	Side effect	Duration (weeks)	Side effect diagnosis	Management	Dupilumab interruption
(18)	1	male	44	atopic dermatitis	Spondyloarthritis	104	laboratory, imaging	secukinumab, baricitinib	yes

**Case reports of uveitis developed due to dupilumab**

Ref.	Case	Sex	Age	Patient history	Side effect	Duration (weeks)	Side effect diagnosis	Management	Dupilumab interruption
(19)	1	female	28	atopic dermatitis	uveitis	4	clinical	local corticosteroid	no
(20)	2	female	57	atopic dermatitis	uveitis	54	clinical	corticosteroid, adalimumab	yes
(21)	3	female	45	atopic dermatitis	uveitis	108	clinical, imaging	corticosteroid, mycophenolate mofetil	yes

**Case reports of IBD developed due to dupilumab**

Ref.	Case	Sex	Age	Patient history	Side effect	Duration (weeks)	Side effect diagnosis	Management	Dupilumab interruption
(22)	1	male	17	atopic dermatitis	ulcerative colitis	12	colonoscopy, biopsy	meselazine	no
(23)	2	female	20	atopic dermatitis	ulcerative colitis	16	colonoscopy, biopsy	meselazine, upadacitinib	yes

Up to 2023, a review study identified 77 cases of psoriasis associated with dupilumab, with one additional case reported from 2023 to March 2024 [3,4]. These patients had initially received dupilumab for various conditions: one for prurigo nodularis, one for asthma, five for chronic rhinosinusitis, and 66 for atopic dermatitis. Four cases had unspecified diagnoses. Among these patients, 49 were male and 29 were female. The average age of the patients developing psoriasis was 40, with an average onset time of psoriasis symptoms 25 weeks after starting dupilumab. The diagnosis was made via biopsy in 41 patients and clinically in 26, while the diagnostic method was not specified for 10 patients (Table 1). Local treatments were used in 41 patients, phototherapy in 3, both local and systemic treatments in 11, and systemic treatment alone in 12; the treatment was unspecified in one case. Dupilumab was discontinued in 41 patients and continued in 34; the continuation status was unspecified in 4 cases. Additionally, another study reported that 3 male patients diagnosed with atopic dermatitis developed psoriasis after an average of 72 weeks. Despite topical treatments, when adequate responses were not obtained, dupilumab was discontinued and phototherapy was initiated [5]. This study's data were not included in our case series, as it did not match our data.

In cases of arthritis related to dupilumab, a total of 15 cases have been reported in three studies and our case [6-8]. Fourteen of these patients had atopic dermatitis, and one had prurigo nodularis. One patient also had allergic asthma and chronic rhinosinusitis. Eight were male and seven were female. The average age of patients with arthritis was 48, and the average onset time of arthritis symptoms after starting dupilumab was 20 weeks. Enthesitis was reported in one patient, arthritis and enthesitis in five, and arthritis alone in nine. Treatment was unspecified in four patients, and except for four, all were given oral NSAIDs. The medication had to be discontinued in seven of the 15 patients. Another study reported musculoskeletal system symptoms in fourteen patients, with six diagnosed with enthesitis and/or inflammatory arthropathy by a rheumatologist. Symptoms developed within 12 weeks in four patients, and within 29 and 36 weeks in two others. Two continued dupilumab with NSAID treatment, one had the dupilumab dosage frequency reduced, and three paused their dupilumab treatment [9]. Another retrospective study of 400 patients treated with at least one dose of dupilumab for atopic dermatitis showed 23 cases of inflammatory enthesitis/arthritis/tenosynovitis, with nine having both enthesitis and arthritis, ten having only enthesitis, three having both enthesitis and tenosynovitis, and one having only arthritis. The average time to clinical symptom emergence was 16 weeks, with NSAID treatment continued during dup-

ilumab therapy. Due to severe symptoms, dupilumab was discontinued in five patients. Some patients temporarily paused treatment but returned to a normal bi-weekly dosage after worsening atopic dermatitis symptoms. Despite dose adjustments, dupilumab was discontinued and baricitinib treatment started for both AD and arthritis in four patients. Another single-center cohort study found inflammatory arthritis/enthesitis/tenosynovitis in 14 males and 12 females. Nonsteroidal anti-inflammatory drugs or cyclooxygenase-2 inhibitors, reducing dupilumab dosage/frequency, and discontinuing dupilumab treatment led to improvement, but moderate or severe symptoms persisted for months [10]. This study's data were not included in our case series.

Three cases of lupus related to dupilumab have been reported, all in female patients with an average age of 34. One had eczema and two had atopic dermatitis. The disease was diagnosed approximately 48 weeks after starting treatment. Patients were treated with hydroxychloroquine, local steroids, systemic steroids, and belimumab. Dupilumab was discontinued in one patient, while treatment continued in two.

Fourteen cases of vasculitis associated with dupilumab have been reported across nine studies. There were four females and ten males with an average age of 54. Ten had EGPA, one had leukocytoclastic vasculitis, one had cutaneous vasculitis, one had eosinophilic vasculitis, and one had pleural effusion. The primary indication for dupilumab treatment in these patients was asthma. Symptoms typically started an average of 12 weeks after initiating dupilumab. All patients were treated with systemic therapy, and the treatment was discontinued in 13 patients.

One case of spondyloarthritis related to dupilumab has been reported. A 44-year-old male diagnosed with atopic dermatitis started on dupilumab, with symptoms emerging 104 weeks post-treatment. The patient was treated with an IL-17 inhibitor and baricitinib, and dupilumab was discontinued.

Three cases of uveitis associated with dupilumab have been reported in three studies. All patients were female, with an average age of 43, diagnosed with atopic dermatitis. Uveitis developed approximately 58 weeks after treatment initiation. Local treatment was preferred in one patient, while systemic treatment was given to two. Dupilumab was discontinued in two patients and continued in one.

Two cases of inflammatory bowel disease related to dupilumab have been reported in two studies. One patient was male, and one was female, with an average age of 18. One was diagnosed with atopic dermatitis and the other with eczema. Symptoms emerged on average 14 weeks after starting treatment. One patient received mesalazine, and the other received mesalazine and upadacitinib. Dupilumab was discontinued in one patient and continued in the other.

## DISCUSSION

Literature reviews have reported side effects resembling inflammatory diseases with the use of dupilumab, most commonly affecting the skin, eyes, and musculoskeletal system. Less frequently, side effects like inflammatory bowel disease, vasculitis, and systemic lupus erythematosus have also been documented [2].

Experimental and therapeutic models have demonstrated the influence of the IL-23/IL-17 cytokine pathway in varying degrees of inflammatory diseases. Studies suggest that dupilumab's mechanism of action through IL-4/IL-13 inhibition leads to a shift towards the IL-23/IL-17 pathway, triggering inflammation. This shift results in a decrease in Th2 responses, subsequently leading to Th1 and associated Th17 dominance [5].

Conditions such as scleroderma, rheumatoid arthritis, dermatomyositis, lupus, polymyalgia rheumatica, and giant cell arteritis have shown limited association with this pathway [2]. However, case reports related to these conditions have been documented in the literature.

The Th2 pathway is influential in the development of lupus. The potential mechanism involves a decrease in Th2 and a shift towards Th17, which is thought to play a role in the development of cutaneous lupus. Case reports have documented lupus-like side effects. Some studies have suggested a possible relationship between atopic dermatitis and lupus, indicating that underlying disease activation should be considered [8]. In none of the case series was systemic lupus developed; the manifestations were limited to the skin. Drug continuation was not possible due to the resistance of skin lesions [9].

Dupilumab has been successfully used in diseases like eosinophilic rhinitis and allergic asthma, based on its suppression of type 2 cytotoxic eosinophilic inflammation through IL-4/IL-13. Additionally, it inhibits the IL-4 VLA-4-VCAM-1 pathway. When this pathway is inhibited, eosinophils cannot migrate to peripheral tissues and accumulate in the circulating blood, causing transient hypereosinophilia [11].

Most patients who developed vasculitis and were treated with dupilumab had allergic rhinitis or allergic asthma. Many developed EGPA after starting dupilumab, possibly due to underlying EGPA that was unmasked by transient hypereosinophilia or discontinuation of corticosteroids that were suppressing EGPA. Another hypothesis is that the drug itself might directly cause this condition [3]. Except for one patient with leukocytoclastic vasculitis, all patients exhibited systemic effects and developed life-threatening conditions. Evaluating all patients for hypereosinophilia and conducting ANCA tests before treatment could predict drug side effects. Additionally, close monitoring while reducing corticosteroid

doses could facilitate side effect management [12]. Ultimately, dupilumab was discontinued in these patients, and aggressive treatments for vasculitis were necessary.

There are two subtypes of the IL-13 receptor: IL-13R $\alpha$ 1, which forms a dimer with IL-4R $\alpha$ , and IL-13R $\alpha$ 2, which does not. Dupilumab does not block the IL-13R $\alpha$ 2 signal. The IL-13 signal mediated by IL-13R $\alpha$ 2 plays a significant role in inflammatory bowel diseases [13]. Similarly, inhibition of IL-17 could produce an inflammatory side effect mimicking ulcerative colitis. Considering that dupilumab activates the IL-17 axis, the role of the IL cascade in ulcerative colitis is quite complex [14].

Studies on the safety of dupilumab have shown that it can cause side effects like ulcerative colitis. Treatment adjustments were made based on the clinical presentations of the patients, and medication had to be discontinued in one of the two cases presented.

The most common side effects identified in safety and side effect studies of dupilumab are ocular findings, typically non-serious and responsive to local treatments like conjunctivitis. More severe conditions, such as uveitis, have been reported much less frequently [1,15].

Dupilumab inhibits IL-4 and IL-13 signaling pathways, leading to decreased goblet cell density and mucin production, reducing tear film stability and causing conjunctival inflammation. The pathogenesis of uveitis in this context remains more ambiguous [16]. There are few reported cases of uveitis in the literature, and some were able to continue with the medication. In one case, the recurrence of uveitis after the drug was restarted supports the suggestion of a drug-related side effect [15].

Another side effect of dupilumab is the activation of herpes. Case series have detected herpes uveitis, which resolved without complications after systemic treatment, without discontinuing dupilumab [10]. Studies have recommended monitoring patients who previously had eye complaints before starting dupilumab [15].

Studies showing that suppression of IL-4 and IL-13 increases IL-23 and IL-17 levels explain why the patterns of musculoskeletal symptoms and findings are characteristic of psoriatic arthritis/peripheral spondyloarthritis [17]. Most patients presented with an enthesitis pattern, and mono or oligoarticular patterns were observed [18].

Generally, for mild mono and oligoarticular symptoms, NSAIDs may be sufficient. For extensive joint involvement, discontinuation of dupilumab should be considered. In cases of severe, widespread involvement, immediate cessation of the medication and commencement of corticosteroid therapy are required [19]. Resistant cases have been successfully



treated with immunosuppressants such as MTX and IL-17 blockers. Nevertheless, the drug was discontinued in seven patients. Long-term follow-ups have shown that symptoms in some patients persisted even after stopping dupilumab [18].

Spondyloarthropathy is a disease group implicated in the pathogenesis of Th17 activation. While dupilumab-related enthesitis and arthritis are common, there is only one case that meets the criteria for spondyloarthropathy, diagnosed after the longest duration of drug use. Perhaps delayed recognition explains this situation [20]. Due to extensive involvement, the drug had to be discontinued, and treatment continued with a JAK inhibitor. The distinction in this case was the demonstration of spinal involvement, suggesting that in patients with a clinic of enthesitis and arthritis, spinal involvement should also be considered.

The mechanism of atopic dermatitis is predominantly Th2-driven, while psoriasis is dominated by Th1 and IL-17. The suppression of IL-4 inhibits Th2, leading to Th1 dominance in this pathway [8]. Additionally, Th2 inhibition also relatively increases the dominance of IL-36 along with IL-17 in the immunopathogenesis of psoriasis [5].

In the literature, skin findings, along with eye symptoms, are among the most frequently reported side effects. Case reports generally show a predominance of plaque-style pustular psoriasis on the upper extremities and the scalp [5]. In case series, side effect management typically involved local and often corticosteroid treatments. About 30% of cases in one series required discontinuation of dupilumab [5].

Interestingly, in a case report involving a patient with both bullous pemphigoid and psoriasis, dupilumab treatment successfully managed both diseases. Researchers noted that the coexistence of both conditions might enhance treatment efficacy, which might not be as effective for psoriasis alone [11].

Generally, the most common side effects observed in the literature include injection site reactions, nasopharyngitis, nausea, and headache, which have been well-managed without needing to discontinue the medication. More side effects have been reported in patients diagnosed with atopic dermatitis, possibly due to the higher number of these patients being treated [10].

In cases with severe side effects, management tried to address the symptoms before discontinuing

the medication, with decisions to stop dupilumab based on the response. In patients with serious or widespread side effects, more aggressive measures were taken to discontinue the drug at the first sign.

Given these side effects, special attention should be given to vasculitis because, except for one case, the side effects presented were life-threatening. One series recommended screening for hypereosinophilia and ANCA before starting the drug, suggesting that vasculitis cases require immediate drug discontinuation and aggressive treatment.

A case report illustrated that disruption of the Th1/Th2 cascade could enhance granulomatous inflammations, leading to neurosarcoidosis in a patient who was started on dupilumab for atopic dermatitis. Rapid improvement was noted after the drug was discontinued [6].

Most patients who started on dupilumab had a history suggestive of a predisposition to inflammatory diseases. Discussions have emphasized that observed side effects might exacerbate an underlying, latent disease or flare diseases suppressed by other medications, such as corticosteroids used before starting treatment. Therefore, reevaluating patients for underlying inflammatory diseases before initiating dupilumab would be prudent.

In our case, a patient who started on dupilumab 12 weeks ago for prurigo nodularis presented with acute left shoulder and knee pain diagnosed with arthritis and treated with intra-articular injection. Follow-ups showed no flare-up in arthritis, and dupilumab treatment continued.

## CONCLUSION

The extent to which Th2-mediated side effects are serious or widespread will become clearer in long-term studies. Lesions resembling psoriasis appear to be the most commonly reported side effect, with 2-3% of patients treated with dupilumab experiencing side effects such as rheumatologic diseases. Predominantly, the dominance of IL-17 leads to findings typically resembling psoriatic and spondyloarthropathy-like manifestations. Changes in the frequency of these side effects over the long term will impact the drug's safety profile. Future studies should focus on understanding the immunogenetics of treated patients to predict the side effect profile more accurately.

*Conflict of interest:* none declared  
*Financial support:* none declared

## REFERENCES

- Deleuran M, Thaçi D, Beck LA, de Bruin-Weller M, Blauvelt A, Forman S, et al. Dupilumab shows long-term safety and efficacy in patients with moderate to severe atopic dermatitis enrolled in a phase 3 open-label extension study. *J Am Acad Dermatol*. 2020 Feb;82(2):377-388. doi: 10.1016/j.jaad.2019.07.074.
- Bridgwood C, Wittmann M, Macleod T, Watad A, Newton D, Bhan K, et al. T Helper 2 IL-4/IL-13 Dual Blockade with Dupilumab Is Linked to Some Emergent T Helper 17-Type Diseases, Including Seronegative Arthritis and Enthesitis/Enthesopathy, but Not to Humoral Autoimmune Diseases. *J Invest Dermatol*. 2022 Oct;142(10):2660-2667. doi: 10.1016/j.jid.2022.03.013.
- Trave I, Salvi I, Burlando M, Cozzani E, Parodi A. „De Novo“ Psoriasis and Relapse of Psoriasis Induced by Dupilumab: Three New Cases and Review of the Literature. *J Clin Med*. 2023 Sep 29;12(19):6291. doi: 10.3390/jcm12196291.
- Liu L, Chen J, Tang K, Li F, Li S, Ding X. Pustular Psoriasis in a Patient Treated with Dupilumab for Atopic Dermatitis: A Case Report. *Clin Cosmet Investig Dermatol*. 2023 Aug 14;16:2217-2221. doi: 10.2147/CCID.S420904.
- Napolitano M, Genco L, Noto M, Fabbrocini G, Patruno C. Parapsoriasis during dupilumab treatment in three patients with a long-lasting history of atopic dermatitis. *J Cosmet Dermatol*. 2024 Feb;23(2):714-716. doi: 10.1111/jocd.15995.
- Jay R, Rodger J, Zirwas M. Review of dupilumab-associated inflammatory arthritis: An approach to clinical analysis and management. *JAAD Case Rep*. 2022;21:14-18. doi: 10.1016/j.jidcr.2021.12.011.
- Woodbury MJ, Smith JS, Merola JF. Dupilumab-Associated Arthritis: A Dermatology-Rheumatology Perspective. *Am J Clin Dermatol*. 2023 Nov;24(6):859-864. doi: 10.1007/s40257-023-00804-5.
- Willsmore ZN, Woolf RT, Hughes C, Menon B, Kirkham B, Smith CH, Pink AE. Development of inflammatory arthritis and enthesitis in patients on dupilumab: a case series. *Br J Dermatol*. 2019 Nov;181(5):1068-1070. doi: 10.1111/bjd.18031.
- Sears AV, Woolf RT, Gribaleva E, Abdelrahman W, Robbie S, Menon B, et al. Real-world effectiveness and tolerability of dupilumab in adult atopic dermatitis: a single-centre, prospective 1-year observational cohort study of the first 100 patients treated. *Br J Dermatol*. 2021 Apr;184(4):755-757. doi: 10.1111/bjd.19631.
- Seishima M, Sasaki M, Hachiken H, Furukawa T, Yagi N, Sugie S. Ulcerative colitis during dupilumab therapy in a patient with atopic dermatitis. *J Dermatol*. 2023 Dec;50(12):e420-e421. doi: 10.1111/1346-8138.16928.
- Hughes CD, Nathan J, Mathew L, Pink AE, Woolf RT, Smith C, et al. Characterization of a Musculoskeletal Syndrome of Enthesitis and Arthritis in Patients With Atopic Dermatitis Treated With Dupilumab, an Interleukin-4/13 Inhibitor. *Arthritis Rheumatol*. 2023 Oct;75(10):1793-1797. doi: 10.1002/art.42558.
- Sekigawa I, Yoshiike T, Iida N, Hashimoto H, Ogawa H. Two cases of atopic dermatitis associated with autoimmune abnormalities. *Rheumatology (Oxford)*. 2003 Jan;42(1):184-5. doi: 10.1093/rheumatology/keg026.
- Jang DH, Lee JI, Bae JY, Jung HJ, Park MY, Ahn J. Facial erythema after the treatment of dupilumab in SLE patient. *Allergy Asthma Clin Immunol*. 2020 Jul 3;16:60. doi: 10.1186/s13223-020-00458-6.
- Tanaka S, Tsuji T, Shiotsu S, Yuba T, Hiraoka N. Exacerbation of Eosinophilic Granulomatosis With Polyangiitis After Administering Dupilumab for Severe Asthma and Eosinophilic Rhinosinusitis With Nasal Polyposis. *Cureus*. 2022 May 22;14(5):e25218. doi: 10.7759/cureus.25218.
- Persaud P, Karmali R, Sankar P, Majid M. Dupilumab-Associated Eosinophilic Granulomatosis With Polyangiitis. *Cureus*. 2022 Aug 4;14(8):e27670. doi: 10.7759/cureus.27670.
- Blumenthal KG, Robinson LB, Camargo CA Jr, Shenoy ES, Banerji A, Landman AB, Wickner P. Acute Allergic Reactions to mRNA COVID-19 Vaccines. *JAMA*. 2021 Apr 20;325(15):1562-1565. doi: 10.1001/jama.2021.3976.
- Shimodaira Y, Takahashi S, Iijima K. Anti-IL-4R $\alpha$  monoclonal antibody dupilumab mimics ulcerative colitis: a case report. *BMC Gastroenterol*. 2021 May 8;21(1):207. doi: 10.1186/s12876-021-01803-8.
- Ayasse M, Lockshin B, Do BK, Kaiser R, Silverberg JI. A case report of uveitis secondary to dupilumab treatment for atopic dermatitis. *JAAD Case Rep*. 2020 Nov 19;7:98-99. doi: 10.1016/j.jidcr.2020.11.012.
- Neagu N, Dianzani C, Avallone G, Dell'Aquila C, Morariu SH, Zalaudek I, Conforti C. Dupilumab ocular side effects in patients with atopic dermatitis: a systematic review. *J Eur Acad Dermatol Venereol*. 2022 Jun;36(6):820-835. doi: 10.1111/jdv.17981.
- Wu D, Daniel BS, Lai AJX, Wong N, Lim DKA, Murrell DF, ET AL. Dupilumab-associated ocular manifestations: A review of clinical presentations and management. *Surv Ophthalmol*. 2022 Sep-Oct;67(5):1419-1442. doi: 10.1016/j.survophthal.2022.02.002.
- De Stefano L, Bobbio-Pallavicini F, Montecucco C, Bugatti S. Dupilumab-induced enthesoarthritis and refractory atopic dermatitis successfully treated with baricitinib. *Rheumatology (Oxford)*. 2022 Mar 2;61(3):e64-e66. doi: 10.1093/rheumatology/keab771.
- Maeno M, Tamagawa-Mineoka R, Arakawa Y, Masuda K, Katoh N. Facial discoid lupus erythematosus during dupilumab treatment for atopic dermatitis. *J Dermatol*. 2022 Jul;49(7):e234-e235. doi: 10.1111/1346-8138.16356.
- Okune M, Okiyama N, Fukuzono M, Sasaki K, Nomura T. Development of systemic lupus erythematosus after dupilumab treatment in a case of atopic dermatitis. *J Dermatol*. 2022 May;49(5):556-559. doi: 10.1111/1346-8138.16322.
- Descamps V, Deschamps L, El Khalifa J, Groh M, Gibier JB, Lefèvre G, Taillé C. Eosinophilic vasculitis associated with persistent dupilumab-induced hypereosinophilia in severe asthma. *Respir Med Res*. 2021 May;79:100821. doi: 10.1016/j.resmer.2021.100821.
- Lommatzsch M, Stoll P, Winkler J, Zeise-Wehry D, Tronnier M, Weber MA, Virchow JC. Eosinophilic pleural effusion and stroke with cutaneous vasculitis: Two cases of dupilumab-induced hypereosinophilia. *Allergy*. 2021 Sep;76(9):2920-2923. doi: 10.1111/all.14964.
- Kai M, Vion PA, Boussouar S, Cacoub P, Saadoun D, Le Joncour A. Eosinophilic granulomatosis polyangiitis (EGPA) complicated with periaortitis, precipitating role of dupilumab? A case report a review of the literature. *RMD Open*. 2023 Sep;9(3):e003300. doi: 10.1136/rmdopen-2023-003300.
- Bach MS, Keeling BH, Yim E. A case of leukocytoclastic vasculitis in a patient on dupilumab. *JAAD Case Rep*. 2023 Sep 24;42:49-51. doi: 10.1016/j.jidcr.2023.08.048.
- Suzaki I, Tanaka A, Yanai R, Maruyama Y, Kamimura S, Hirano K, Kobayashi H. Eosinophilic granulomatosis with polyangiitis developed after dupilumab administration in patients with eosinophilic chronic rhinosinusitis and asthma: a case report. *BMC Pulm Med*. 2023 Apr 19;23(1):130. doi: 10.1186/s12890-023-02415-6.
- Eger K, Pet L, Weersink EJM, Bel EH. Complications of switching from anti-IL-5 or anti-IL-5R to dupilumab in corticosteroid-dependent severe asthma. *J Allergy Clin Immunol Pract*. 2021 Jul;9(7):2913-2915. doi: 10.1016/j.jaip.2021.02.042.
- Raimondo A, Guglielmi G, Marino C, Ligrone L, Lembo S. Acute spondyloarthritis developing during successful treatment with dupilumab for severe atopic dermatitis. *Clin Exp Dermatol*. 2022 Mar;47(3):592-593. doi: 10.1111/ced.14984.
- Zhang S, Lu L, Feng J, Hu Z, Song H, Yang L, et al. Uveitis and hypereosinophilia associated with dupilumab in an atopic dermatitis patient. *J Dermatolog Treat*. 2023 Dec;34(1):2229466. doi: 10.1080/09546634.2023.2229466.
- Padidam S, Raiji V, Moorthy R, Oliver A, Do B. Association of Dupilumab with Intraocular Inflammation. *Ocul Immunol Inflamm*. 2022 Jul;30(5):1068-1073. doi: 10.1080/09273948.2020.1861305.
- Flanagan KE, Pupo Wiss IM, Pathoulas JT, Walker CJ, Senna MM. Dupilumab-induced psoriasis in a patient with atopic dermatitis and alopecia totalis: A case report and literature review. *Dermatol Ther*. 2022 Feb;35(2):e15255. doi: 10.1111/dth.15255.
- Liu JH, Gao Q, Ma WY, Cheng ZL, Luo NN, Hao PS. Successful Treatment of Psoriasis Combined with Bullous Pemphigoid with Dupilumab: A Case Report. *Clin Cosmet Investig Dermatol*. 2023 Jun 20;16:1583-1587. doi: 10.2147/CCID.S415019.
- Tsitos S, Niederauer LC, Albert I Gracenea P, Mueller J, Straube A, Von Baumgarten L. Case Report: Drug-Induced (Neuro) Sarcoidosis-Like Lesion Under IL4 Receptor Blockade With Dupilumab. *Front Neurol*. 2022 Jun 20;13:881144. doi: 10.3389/fneur.2022.881144.