

# Statins and muscle – friends or foes? Discussions based on a case report

Andra Patricia Stanciu<sup>1</sup>, Cristina Nita<sup>1</sup>, Laura Groseanu<sup>1,2</sup>

<sup>1</sup>“Sfanta Maria” Clinical Hospital, Bucharest Romania

<sup>2</sup>“Carol Davila” University of Medicine and Pharmacy, Bucharest, Romania

## ABSTRACT

Immune-mediated necrotizing myopathy (IMNM) is a type of autoimmune myopathy characterized by relatively severe proximal weakness, myofiber necrosis with minimal inflammatory cell infiltrate on muscle biopsy, and infrequent extra-muscular involvement. Anti-3-hydroxy-3-methylglutaryl-CoA reductase (HMGCR) myopathy is a distinct subtype of IMNM, often associated with statin exposure. Treatment of IMNM consists of immunosuppression with steroids, steroid-sparing agents, intravenous immune globulin and/or biologics. We present here a case of anti-HMGCR-associated IMNM and a brief review of the pathophysiology, diagnosis and treatment to increase physician awareness of this rare and debilitating condition.

**Keywords:** statins, immune mediated necrotizing myopathy

## INTRODUCTION

The statins, 3-hydroxy-3-methylglutaryl-CoA reductase (HMGCR) inhibitors, are a widely used class of lipid-lowering drugs due to their efficacy and safety profile. However, muscle toxicity is one of the most common side effects of these medications. Statin-related myotoxicity (SRM) can range from asymptomatic increase in serum muscle enzymes levels or myalgias to self-limited myopathy and rhabdomyolysis [1]. Also, since the 2000s, cases of statin-induced immune-mediated necrotizing myopathy (IMNM) have been reported [2-3]. In 2010, specific autoantibodies associated with this myopathy were discovered - anti-HMGCR antibodies - introducing the notion of anti-HMGCR myositis [4].

## CASE REPORT

We present the case of a 65-year-old female patient with a history of hyperlipidemia, arterial hypertension, coronary artery disease and type 2 diabetes mellitus, evaluated in our rheumatology department for symmetrical proximal muscle weakness and myalgias started one year prior hos-

pitalization in our unit. Due to high cardiovascular risk, the patient has been taking regular doses of statins for a couple of years, but after an acute coronary syndrome, she was recommended high doses (simvastatin 80 mg/day). Soon after the dose was increased, the patient developed myalgias and the CK levels increased up to 11.000 UI/ml. Despite lowering the statins dose and finally discontinuation, the CK levels persisted at very high levels. At that time, infectious (hepatitis B, hepatitis C, human immunodeficiency virus - HIV, *Trichinella spiralis*, *Toxoplasma gondii*, *Toxocara canis*), endocrinological (hypo/hyperthyroidism) and malignant (thoracic and abdominal computed tomography) causes of myopathy were ruled out.

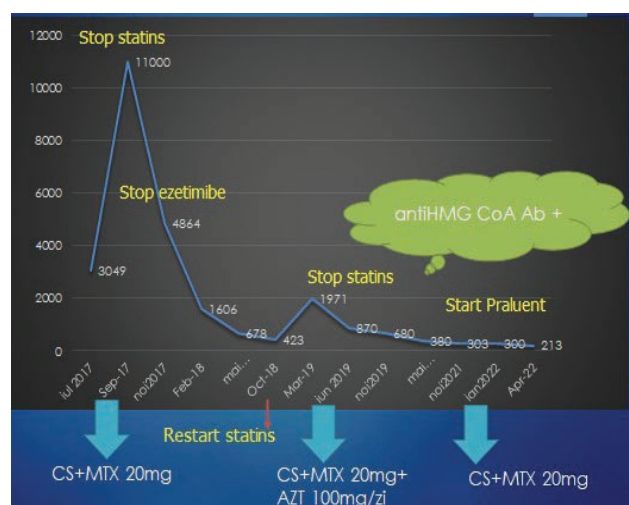
Upon admission in our department, laboratory findings revealed significant elevation of serum muscle enzymes levels - creatine kinase (CK) x 10 the upper limit of normal (ULN), inflammatory markers within normal ranges and a negative anti-nuclear antibody and myositis antibody profile.

Electromyography (EMG) and muscle biopsy were performed. The EMG showed proximal inflammatory myopathy - features compatible with the diagnosis of polymyositis and the muscle biopsy re-

vealed interstitial inflammatory infiltrate composed of lymphocytes and plasmocytes and rare atrophic muscle fibers.

Based on these investigations, the patient was diagnosed with polymyositis and treatment was initiated - methylprednisolone (0.8 mg/kg) along with a corticosteroid-sparing agent – methotrexate 10 mg/week. At the 6 months follow-up, the patient reported improved muscle strength and the laboratory data showed regression of the serum muscle enzymes levels but still at levels up to 3 - 4 times ULN and significant elevation of the cholesterol level. Due to poor diabetes control, we decided to taper the glucocorticoid and to increase the methotrexate dose to 20mg/week.

It is worth mentioning that in this period of time, given the patient's cardiovascular risk, lipid-lowering therapy was attempted both ezetimibe and rosuvastatin, but soon after initiation the CK level gradually increased each time. One year later, the patient presented with proximal muscle weakness and CK x 10 ULN. Supplementary laboratory tests revealed positive anti-HMGCR antibodies. Due to the symptoms and the marked elevation of CK, a second immunosuppressant was added to the treatment - azathioprine 50 mg/day increasing to 100 mg/day.



**FIGURE 1.** Patient evolution  
CS-orticosteroids, MTX-Methotrexate, AZT-azathioprine

Taking into account the clinical manifestations and laboratory data (CK x 10 ULN) with no improvement upon discontinuation of statin treatment and the presence of anti-HMGCR antibodies, the diagnosis of immune mediated necrotizing myopathy was established.

She continued the combination of Azathioprine 100 mg/day and Methotrexate 20 mg/week for 18 months, then Azathioprine was stopped; corticosteroids were gradually tapered upon discontinuation. The follow up was good, asymptomatic and normal CK levels. Due to high cardiovascular risk, lipid-low-

ering treatment with alirocumab was initiated. No adverse events were noted.

## DISCUSSION

Statins (HMGCR inhibitors) are the first-line therapy for hyperlipidemias due to their efficiency in reducing cardiovascular risk and cardiovascular mortality, as well as their good safety profile. However, myotoxicity is a relatively common side effect of statin treatment. Statins related myopathy (SRM) includes a heterogeneous group of muscle side effects ranging from mild-to-moderate myalgia and weakness to myositis and rhabdomyolysis [5].

Several classifications have been proposed for SRM, but there is no consensus [6,7,8]. Most often, in clinical practice, a simple classification composed of 4 phenotypes is used: asymptomatic hyperCKemia, myalgia, self-limited myopathy and immune mediated necrotizing myopathy (IMNM) - anti-HMGCR myositis. Up to 20% of patients exposed to statins report muscle symptoms, but the majority of these symptoms are due to statin-induced direct toxicity and these patients do not develop anti-HMGCR autoantibodies [9].

IMNMs are a subgroup of inflammatory idiopathic myopathies (IIM) and are classified into 3 separate subgroups: anti-HMGCR myositis, anti-signal recognition particle (SRP) myositis and antibody-negative myositis. Anti-HMGCR myositis is the only type of IMNM related to statin use [10].

IMNM is the most recently described statin-associated myopathy with three case series published in the early 2000s [2-3]. Later, in 2010, specific autoantibodies associated with this myopathy were discovered - anti-HMGCR antibodies [4].

Numerous hypotheses have been studied regarding the pathogenesis of SRM, but none have been unequivocally proved. Factors that may play a role in the pathogenesis of SRM include genetic polymorphisms involved in statin metabolism and pharmacokinetics, mitochondrial dysfunction, inhibition of the HMGCR/mevalonate pathway, coenzyme Q10 deficiency and decreased protein prenylation [5].

Regarding anti-HMGCR myositis, statins could contribute to breaking immune tolerance to HMGCR in susceptible patients. Statins are known to upregulate HMGCR and this could lead to abnormal processing of the enzyme with presentation of highly immunogenic HMGCR neoantigens, thus triggering the autoimmune disease [9]. Also, genetic predisposing factors have been identified - human leukocyte antigen (HLA) DRB1\*11:01 [11].

The clinical manifestations of SRM vary widely in severity from asymptomatic to life-threatening rhabdomyolysis.

In the present case, the patient had been treated with statins for about 3 years when she had muscle weakness associated with elevated CK x 10 ULN. Other causes of myopathy (infectious, endocrinological, paraneoplastic) were ruled out and the diagnosis of SRM was considered. Thus, it was decided to discontinue statin treatment. Upon admission in our department, muscle symptoms and CK elevation persisted despite statin withdrawal. At that point, several differential diagnoses were considered. First, it was necessary to differentiate between the SRM phenotypes (Table 1). Second, IIMs should be also taken into account.

Most often, the onset of SRM occurs within the first 6 months of statin treatment. However, in the case of anti-HMGCR myositis, the onset of symptoms may be up to 3 years after statin initiation [9].

Our patient had been treated with statin for 3 years before the onset of muscle symptoms.

**TABLE 1.** Statin-related myotoxicity phenotypes [9,10]

Phenotype	Incidence	Characteristics
HyperCKemia	9 - 20%	Asymptomatic
Myalgia	0.3 - 33%	Muscle pain without CK elevation/CK <4 x ULN
Myopathy	5/100000 patient – years	CK elevation >4 x ULN, <50 x ULN, progressive muscle weakness, complete resolution after statin withdrawal
Rhabdomyolysis	0.1 - 8.4/100000 patient - years	CK elevation >50 x ULN with renal impairment + muscle symptoms
Anti-HMGCR myositis	2/million per year	Muscle symptoms, anti-HMGCR antibodies, CK elevation 10 - 100 x ULN, no improvement after statin withdrawal

CK - creatin kinase, HMGCR - 3-hydroxy-3-methylglutaryl-CoA reductase, ULN - upper limit of normal

Also, in patients with statin-induced myopathy, statin withdrawal leads to good outcomes without the need for further therapeutic interventions. In patients with anti-HMGCR myositis, statin withdrawal does not usually improve the symptoms [11].

Regarding histological findings, in statin-induced myopathy, muscle biopsy reveals necrosis and regenerating muscle fibers, but no immune features. However, it is known that regenerating muscle fibers can express major histocompatibility complex (MHC) class I and it may be difficult to establish whether the histological findings indicate an immune-mediated disease [9]. In the case of anti-HMGCR myositis, the typical features include different stages of muscle cell necrosis, regeneration and myophagocytosis. Inflammatory infiltrate can be pres-

ent and it is mainly composed of macrophages, but CD4+ or CD8+ lymphocytes and plasmacytoid dendritic cells can also be found [12]. The presence of MHC class I on the sarcolemma is multifocal and deposition of membrane attack complex (MAC) on the sarcolemma is observed on a variable number of non-necrotic myofibers [13].

In our case, muscle biopsy was less characteristic showing inflammatory infiltrate composed of lymphocytes and plasmocytes, without muscle fibers necrosis or regeneration. These misleading histological features led the diagnosis to polymyositis.

It is worth mentioning that polymyositis and IMNM were not separated in the subclassification tree established in the 2017 EULAR/ACR classification of IIM. It was not possible to make this distinction because only a few patients with IMNM were included in the study [14].

Nevertheless, IMNM is recognized as a separate subclass of IIM. This subtype includes 3 different entities: anti-SRP myositis, anti-HMGCR myositis and antibody-negative myositis. All three are characterized by proximal muscle weakness and increased CK values. For the diagnosis of the first two, these criteria associated with antibody positivity are sufficient. Muscle biopsy is not required [13].

As noted in this case, muscle biopsy can sometimes be misleading. Given the similar histological features between statin-induced myopathy and IMNM, the detection of antibodies is of particular importance for the diagnosis of anti-HMGCR myositis [9].

In the present case, the diagnosis of IMNM - anti-HMGCR myositis was established based on the presence of anti-HMGCR antibodies and the clinical features (proximal muscle weakness) associated with increased CK >10 ULN despite statin treatment withdrawal.

Anti-HMGCR myositis is a rare disease with a prevalence of 2 cases per million people and accounts for 6 to 10% of IIMs. It is more common in women over 40 years of age. Studies show that the percentage of statin exposure in these patients varies between 16-65%, but in patients over 50 years of age the percentage reaches 90% [13].

The clinical manifestations are similar to those of other IIMs - symmetrical proximal muscle weakness predominantly in the lower limbs with a significant increase in CK values (10 - 100 x ULN). Also, anti-HMGCR myositis seems to be associated with severe muscle damage and atrophy. Currently, no extramuscular manifestations have been considered to be part of the disease phenotype [13].

IMNMs, particularly anti-HMGCR myositis, are relatively new diseases and in the absence of evidence provided by randomized, controlled trials, treatment is based on case reports and expert consensus.

In 2016, the European Neuromuscular Centre (ENMC) working group elaborated a set of recommendations for induction and maintenance therapy in patients with IMNM. Initial treatment should include intravenous and/or oral glucocorticoids with the addition of a corticosteroid sparing agent at the same time or within a month. Methotrexate can be used as a first-line corticosteroid sparing agent. In case of methotrexate intolerance, other options include azathioprine and mycophenolate mofetil. In severe cases, combinations of immunosuppressive agents may be used. Also, in refractory/relapsing patients rituximab may be attempted [10].

In our patient, the initial therapy included oral glucocorticoids and methotrexate. Under this treatment, the patient relapsed and it was decided to add a second immunosuppressive agent.

In patients with anti-HMGCR myositis, the ENMC guidelines also recommend the use of intravenous immunoglobulins (IVIG) in refractory cases [10].

Furthermore, one small study reported the efficacy of IVIG monotherapy in patients with anti-HMGCR myositis and contraindications to glucocorticoids [15]. Currently, a phase 2, randomized, placebo-controlled, on-going trial is testing the efficacy of IVIG monotherapy in patients with anti-HMGCR myositis [16].

Regarding SRM (muscle symptoms and/or CK >4 x ULN), stopping the statin for 2-4 weeks is recommended. If clinical improvement occurs, rechallenge therapy with a lower dose of the same statin/another statin or non-daily dosing strategy may be attempted [5].

If the resolution of the symptoms is not observed, the diagnosis of anti-HMGCR myositis or other IIM should be taken into consideration.

Considering that statin exposure is a trigger for anti-HMGCR myositis, statin should be discontinued

in these patients. As in the case presented, the treatment of hypercholesterolemia in these patients may be challenging.

Along with lifestyle and diet therapy, non-statin therapeutic options for hyperlipidemia include ezetimibe, bile acid sequestrants and new biological treatments as alirocumab. Ezetimibe is the first line of treatment indicated for statin-intolerant patients. It can reduce the low-density lipoprotein (LDL) cholesterol by 15-20% by inhibiting the absorption of dietary and biliary cholesterol in the small bowel. Bile sequestrants in combination with ezetimibe can reduce LDL cholesterol by 30-35% [5].

In the case presented, taking into account the patient's cardiovascular risk and ezetimibe inefficacy, it was decided to start treatment with alirocumab. Alirocumab is a monoclonal antibody against proprotein convertase subtilisin/kexin type 9 (PCSK9). PCSK9 regulates degradation of the hepatic low density lipoproteins receptor. Studies have shown that its inhibition can lower LDL cholesterol by 50–70% in monotherapy or in combination with a statin [17]

## CONCLUSION

Anti-HMGCR myositis is a rare statin-induced IMNM that should be taken into account in any patient with SRM that does not improve after statin withdrawal. Autoantibody testing is mandatory for diagnosis. In the absence of evidence provided by randomized, controlled trials, therapeutic strategy is based on expert consensus and it includes statin discontinuation, glucocorticoids, immunosuppressive agents and IVIG. Novel lipid-lowering drugs such as PCSK9 inhibitors can be useful in treating hypercholesterolemia in these patients.

*Conflict of interest:* none declared

*Financial support:* none declared

## REFERENCES

1. Sathasivam S, Lecky B. Statin induced myopathy. *BMJ*. 2008 Nov 6;337:a2286. doi: 10.1136/bmj.a2286. PMID: 18988647
2. Fauchais AL, Iba Ba J, Maurage P, Kyndt X, Bataille D, Hachulla E et al. Polymyosites induites ou associées aux traitements hypolipémiants? A propos de cinq cas [Polymyositis induced or associated with lipid-lowering drugs: five cases]. *Rev Med Interne*. 2004 Apr;25(4):294-8. doi: 10.1016/j.revmed.2003.10.013. PMID: 15050796.
3. Needham M, Fabian V, Knezevic W, Panegyres P, Zilko P, Mastaglia FL. Progressive myopathy with up-regulation of MHC-I associated with statin therapy. *Neuromuscul Disord*. 2007 Feb;17(2):194-200. doi: 10.1016/j.nmd.2006.10.007. Epub 2007 Jan 22. PMID: 17241784.
4. Christopher-Stine L et al. A novel autoantibody recognizing 200-kd and 100-kd proteins is associated with an immune-mediated necrotizing myopathy. *Arthritis Rheum*. 2010;62(9):2757–66.
5. Vinci P, Panizon E, Tosoni LM, Cerrato C, Pellicori F, Mearelli F et al. Statin-Associated Myopathy: Emphasis on Mechanisms and Targeted Therapy. *Int J Mol Sci*. 2021 Oct 28;22(21):11687. doi: 10.3390/ijms222111687. PMID: 34769118; PMCID: PMC8583847.
6. Alfrevic A, Neely D, Armitage J, Chinoy H, Cooper RG, Laaksonen R et al. Phenotype standardization for statin-induced myotoxicity. *Clin Pharmacol Ther*. 2014 Oct;96(4):470-6. doi: 10.1038/clpt.2014.121. Epub 2014 Jun 4. PMID: 24897241; PMCID: PMC4172546.
7. Stroes ES, Thompson PD, Corsini A, Vladutiu GD, Raal FJ, Ray KK et al. European Atherosclerosis Society Consensus Panel. Statin-associated muscle symptoms: impact on statin therapy—European Atherosclerosis Society Consensus Panel Statement on Assessment, Aetiology and Management. *Eur Heart J*. 2015 May 1;36(17):1012-22. doi: 10.1093/eurheartj/ehv043. Epub 2015 Feb 18. PMID: 25694464; PMCID: PMC4416140.

8. Pasternak RC, Smith SC Jr, Bairey-Merz CN, Grundy SM, Cleeman JI, Lenfant C. American College of Cardiology. American Heart Association. National Heart, Lung and Blood Institute. ACC/AHA/NHLBI clinical advisory on the use and safety of statins. *J Am Coll Cardiol*. 2002 Aug 7;40(3):567-72. doi: 10.1016/s0735-1097(02)02030-2. PMID: 12142128.
9. Selva-O'Callaghan A, Alvarado-Cardenas M, Pinal-Fernández I, Trallero-Araguás E, Millisenda JC, Martínez MÁ et al. Statin-induced myalgia and myositis: an update on pathogenesis and clinical recommendations. *Expert Rev Clin Immunol*. 2018 Mar;14(3):215-224. doi: 10.1080/1744666X.2018.1440206. Epub 2018 Feb 23. PMID: 29473763; PMCID: PMC6019601.
10. Allenbach Y, Mammen AL, Benveniste O, Stenzel W. Immune-Mediated Necrotizing Myopathies Working Group. 224th ENMC International Workshop: Clinico-sero-pathological classification of immune-mediated necrotizing myopathies Zandvoort, The Netherlands, 14-16 October 2016. *Neuromuscul Disord*. 2018 Jan;28(1):87-99. doi: 10.1016/j.nmd.2017.09.016. Epub 2017 Oct 23. PMID: 29221629.
11. Mammen AL, Gaudet D, Brisson D, Christopher-Stine L, Lloyd TE, Leffell MS, Zachary AA. Increased frequency of DRB1\*11:01 in anti-hydroxymethylglutaryl-coenzyme A reductase-associated autoimmune myopathy. *Arthritis Care Res (Hoboken)*. 2012 Aug;64(8):1233-7. doi: 10.1002/acr.21671. PMID: 22422616; PMCID: PMC3400716.
12. Pinal-Fernandez I, Casal-Dominguez M, Mammen AL. Immune-Mediated Necrotizing Myopathy. *Curr Rheumatol Rep*. 2018 Mar 26;20(4):21. doi: 10.1007/s11926-018-0732-6. PMID: 29582188; PMCID: PMC6019613
13. Allenbach Y, Benveniste O, Stenzel W, Boyer O. Immune-mediated necrotizing myopathy: clinical features and pathogenesis. *Nat Rev Rheumatol*. 2020 Dec;16(12):689-701. doi: 10.1038/s41584-020-00515-9. Epub 2020 Oct 22. PMID: 33093664.
14. Lundberg IE, Tjärnlund A, Bottai M, Werth VP, Pilkington C, Visser M et al. International Myositis Classification Criteria Project consortium, The Euromyositis register and The Juvenile Dermatomyositis Cohort Biomarker Study and Repository (JDRG) (UK and Ireland). 2017 European League Against Rheumatism/American College of Rheumatology classification criteria for adult and juvenile idiopathic inflammatory myopathies and their major subgroups. *Ann Rheum Dis*. 2017 Dec;76(12):1955-1964. doi: 10.1136/annrheumdis-2017-211468. Epub 2017 Oct 27. Erratum in: *Ann Rheum Dis*. 2018 Sep;77(9):e64. PMID: 29079590; PMCID: PMC5736307.
15. Mammen AL, Tiniakou E. Intravenous Immune Globulin for Statin-Triggered Autoimmune Myopathy. *N Engl J Med*. 2015 Oct 22;373(17):1680-2. doi: 10.1056/NEJMc1506163. PMID: 26488714; PMCID: PMC4629845.
16. Monotherapy IVIG Gamunex-C for HMG-CoA Reductase Auto-Antibody Positive Necrotizing Myopathy Treatment (The MIGHT Trial) <https://clinicaltrials.gov/ct2/show/NCT04450654>
17. Everett BM, Smith RJ, Hiatt WR. Reducing LDL with PCSK9 Inhibitors--The Clinical Benefit of Lipid Drugs. *N Engl J Med*. 2015 Oct 22;373(17):1588-91. doi: 10.1056/NEJMp1508120. Epub 2015 Oct 7. PMID: 26444323.