

Rare case of female Behçet's disease with urological involvement

Claudia Cobilinski^{1,2}, Catalin Belinski³, Daniela Opris-Belinski^{1,2}

¹„Carol Davila“ University of Medicine and Pharmacy, Bucharest, Romania

²„St. Maria“ Clinical Hospital, Bucharest, Romania

³„Prof. Dr. Dimitrie Gerota“ Emergency Hospital, Bucharest, Romania

ABSTRACT

Behçet's disease is a systemic vasculitis with several well-defined organ manifestations, including various mucocutaneous features. Among them, the urinary tract involvement is rarely cited, most data focusing on bladder dysfunction due to neuroBehçet. This article presents a rare case of a young female patient with urological complaints that was diagnosed with right ureteral ulceration, later confirmed as vasculitis at the histopathological examination. Urological intervention together with adequate immunosuppression led to the healing of the ulcerative lesion. The unusual vasculitic lesion site indicates the complexity of Behçet's disease that requires careful investigation and treatment.

Keywords: Behçet's disease, ureteral ulceration, ureteral stent, immunosuppressant

INTRODUCTION

Behçet's disease (BD) is a variable size vasculitis that can affect both arteries and veins characterized by recurrent episodes of orogenital ulcers, eye and skin involvement, neurologic manifestations accompanied by a positive patergy test (1). The genetic background is best described by HLA B51 positivity which associates with a more extensive clinical expression of the disease (2).

While the above-mentioned organ involvement are well described in the disease related literature, including disease revised criteria and management guidelines, urological suffering related to the urinary tract is rarely mentioned as possible in BD or received any specific indications for treatment (3).

Considering ureteral lesions as an exquisitely rare manifestation in BD, we present the case of a female patient with this type of involvement.

CASE REPORT

We present the rare case of a 34-year old female patient diagnosed with Behçet's disease since August 2015 who was admitted in the Rheumatology Department for her regular follow-up while complaining of dysuria and right lumbar pain.

The onset of the disease was in 2013 when the patient presented to her general practitioner (GP) for repeated febrile episodes that were essentially vesperal, occurring in the afternoon followed by odynophagia and painful aphthae on her oral mucosa. Due to her prominent ENT symptoms, her GP referred the patient to a specialist who prescribed multiple antibiotic schemes because of the high suspicion of streptococcal infection. Lack of patient response to antibiotherapy, recurrent fever and negative throat cultures led the patient further to search for an infectionist's opinion. The latter pointed out the presence of multiple aphthous lesions on the patient's hard and soft palate, jugal mucosa and tonsils. Several etiologies were excluded on this occasion, including hepatitis B, C, HIV, herpes infections, vitamin deficiencies or inflammatory bowel diseases.

The patient was further transferred to a territorial Rheumatology Department where multiple diagnoses were investigated. Meanwhile, the patient complained of inflammatory arthralgias in her small joints of the hands and alopecia which might have suggested the diagnosis of systemic lupus erythematosus. However, complement levels were normal and antibodies (anti-nuclear antibodies, double-strandedDNA) were negative. Rheumatoid ar-

Corresponding author:

Catalin Belinski

E-mail: drbelinski@yahoo.com

Article History:

Received: 16 May 2019

Accepted: 30 May 2019

thrititis was ruled out based on the ultrasound aspect of the joints that showed no typical erosions, both rheumatoid factor (RF) and anti-citrullinated protein antibodies (ACPA) were negative. The patient only exhibited a moderate inflammatory syndrome.

Patient's history added subsequent essential details such as an episode of genital aphthous lesions, acnea and positive patergy test that together with the presence of the HLA-B51 gene concurred to the diagnosis of Behçet's disease, two years after symptom onset. Treatment with colchicine, azathioprine and glucocorticoids (GC) was promptly initiated.

The patient was later on regularly monitored in our University Clinic with episodes of disease flare that manifested with recurrent extensive ulcerative lesions on her tonsils that required a therapeutic switch on cyclosporine and careful adjustment of GC dose.

In June 2018 the patient was admitted for dysuria and slight pain in her right lumbar area. Abdominal ultrasound at the time highlighted a stage 2 hydronephrosis that inquired repeated ureteroscopic examinations and finally the placement of a Cook ureteral stent, with no obvious lesion at the time. Persistent pain, hematuria (Figure 1) and aggravation to a stage 5 hydronephrosis appeared after the stent was initially removed. Patient deterioration required a tomographic imaging that mentioned a severe stenosis of the right pelvic ureter. This finding was followed by a pelvic MRI that ruled out the presence of a com-

pressive tumor that might have led to these stenotic changes.



FIGURE 1. Collected urine with hematuric aspect

The patient's renal function deteriorated and it was accompanied by fever, leukocytosis and positive urine cultures that required prompt sanction of the stent. A following ureteroscopic investigation was conducted in another Urology Department where the stent was replaced but surprisingly noticing a ulcerative lesion on the right ureter (Figure 2). The team questioned if the ulcer was due to repeated ureteroscopic interventions that might have injured the mucosa on site or if it was a consequence of her yet uncontrolled vasculitis. Thus, a biopsy was made.

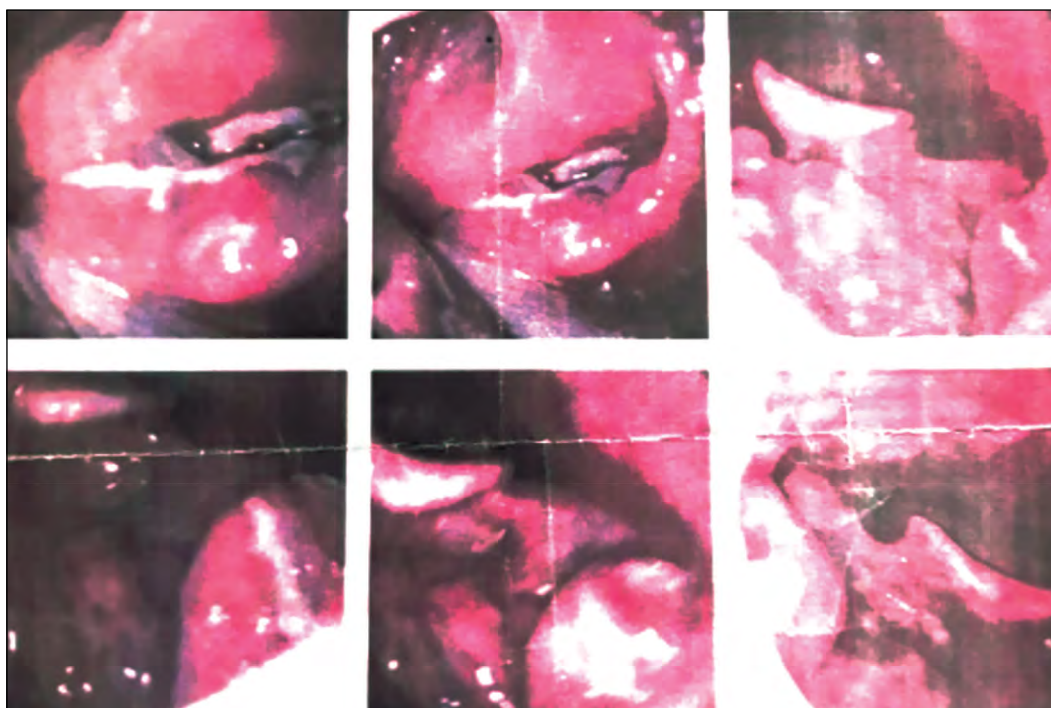

FIGURE 2. Ureteroscopic aspect of the mucosal ulcerative lesion

The histopathological finding showed urothelium fragments with reactive changes, intraepithelial edema, the connective tissue had a lymphocytic inflammatory infiltrate as well as polymorphonuclear cells in the interstitial and perivascular structures. These changes confirmed signs of vasculitis compatible with the patient's formerly established diagnosis.

At the time of the ureteral intervention, the patient was on methotrexate at a dose of 10 milligrams per week due to incomplete response to previous immunosuppressants. Taking into account the severe and unusual site of disease activity, the past lack of response to azathioprine, she was put again on cyclosporine 100mg daily together with 1mg of colchicine and a descending dose of GC.

Figure 3 depicts the ureteroscopic findings after 6 months of treatment, showing a significant improvement of the ureteral lesion. Its persistence led to the decision to maintain the ureteral stent for a longer interval in order to ensure the complete healing of the ulceration.

Periodic urological reevaluations showed a slow healing of the ureteral ulcer and the integrity of the ureteral mucosa that allowed the stent removal in March 2019 with no further discomfort in the uro-

genital area together with normalization of the renal function and ultrasound aspect.

DISCUSSIONS

Behçet's disease is a multisystemic vasculitis affecting any size and type of vessels. Classical organ involvement include mucocutaneous, cardiovascular, neurological and ocular features. Apart from genital aphthous lesions and epididymitis (4), other urological manifestations are rarely cited. For example, the incidence of bladder manifestations, mostly urodynamic changes, were identified by Cetinel et al. to be at around 0.07% in BD patients. He suggested that urological involvement can be present 1 to 10 years after the onset of the disease.

Bladder involvement was reviewed in 2011 by Alizadeh et al. based on case reports and case series (5). Authors included in their online data search neuropathic bladder issues, voiding dysfunctions and urologic symptoms. They found out that most patients with this system manifestations were middle-aged males with storage problems because of a deficient sphincter. They also found reasons for dysuria in BD patients such as meatal ulceration, sterile

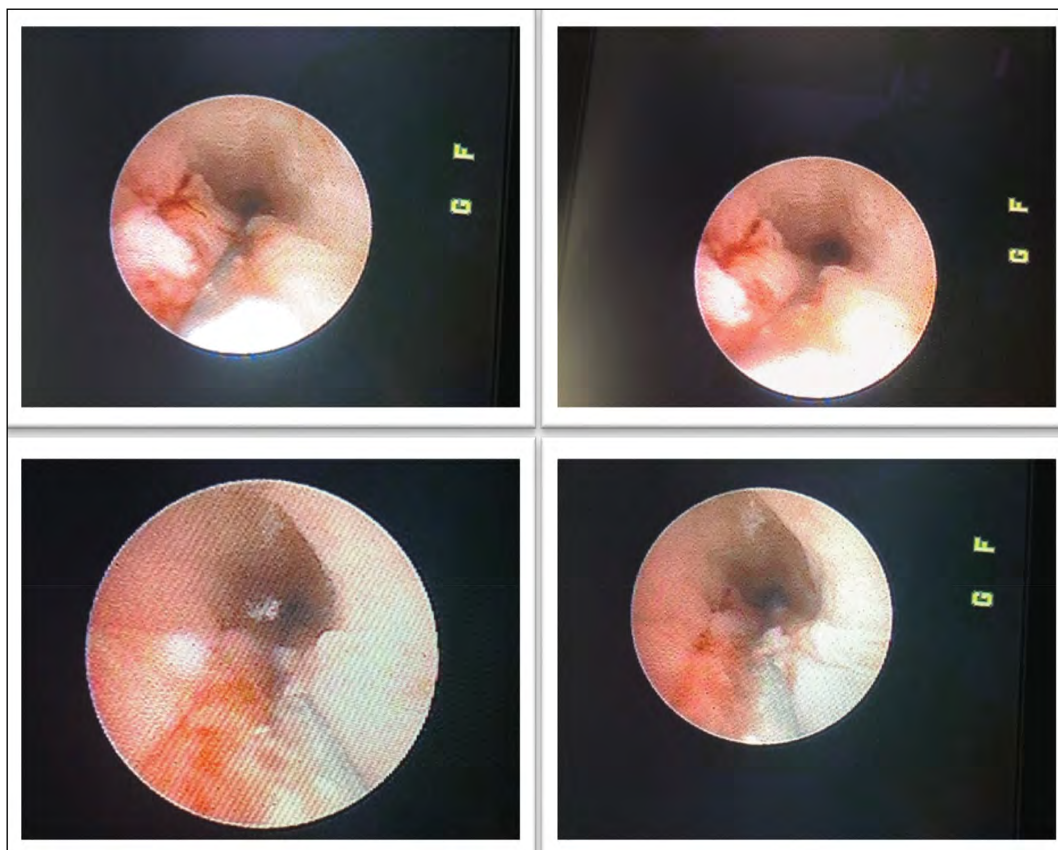


FIGURE 3. Ureteroscopic control reevaluation after 6 months of treatment

urethritis or cystitis. Cyclophosphamide treatment was the cause for most bladder located cancers in this patient category, but the rate was not higher than in other patients (6). Rare urethrovaginal fistulas were identified.

Bladder ulcers were cited as possible after being confirmed by cystoscopic examination and were suggested to be self-limited (7).

A cumulative analysis on renal Behçet's published in 2012 estimated a rate up to 55% for this organ involvement, the male gender representing a risk factor. Among renal features, BD can manifest itself with AA amyloidosis, glomerulonephritis ranging from hematuria and proteinuria to rapidly progressive disease (8). Vascular involvement may manifest through renal artery aneurysms, renal vein thrombosis or microscopic lesions. The article suggests that renal involvement, under all forms, is more frequent than recognized in BD (8).

A case report published in 2013 emphasized the severity of a urethral ulcer in a 16 year old male patient, with consequent urethral meatal stenosis that required retrograde urethrography for a correct diagnosis (9).

In 2018, EULAR released recommendations for the management of Behçet's syndrome, indicating

that recurrent lesions that are reluctant to colchicine alone should be accompanied by immunomodulatory or immunosuppressive drugs (azathioprine, thalidomide, interferon-alpha, anti-TNFs or apremilast) (10). Other biologics targeting interleukin-1 (IL-1), such as anakinra or canakinumab can be used in mucocutaneous BD providing some benefits to the suffering (10).

CONCLUSIONS

The present article is about a case of BD complicated with ureteral ulceration that was confirmed in the histopathological examination. Behçet's disease with ureteral ulcerative lesions is a rarely encountered entity, even more so in female patients that usually present with skin involvement and less severe organ involvement (11). Specific recommendations for this type of complication are not yet available, therefore we suggest that a multidisciplinary approach should be envisioned in these patients. A team of rheumatologists and urologists should collaborate, knowing that both disease activity and local surgical procedures are required in order to obtain optimal results in severe BD patients.

REFERENCES

1. Talarico R, Bombardieri S. Behçet disease. In: *Systemic Vasculitides: Current Status and Perspectives*. 2016:225-232. doi:10.1007/978-3-319-40136-2_20.
2. Abdelmuktader A. Genetic Evidence in Behçet Disease Pathogenesis. *Viral Immunol J*. 2018;2(1). doi:10.23880/vij-16000136.
3. Yazici H, Seyahi E, Hatemi G, Yazici Y. Behçet syndrome: A contemporary view. *Nat Rev Rheumatol*. 2018;14(2):107-119. doi:10.1038/nrrheum.2017.208.
4. Yılmaz O, Yılmaz S, Kisacik B et al. Varicocele and epididymitis in Behçet disease. *J Ultrasound Med*. 2011;30(7):909-913. doi:10.7863/jum.2011.30.7.909.
5. Alizadeh F, Khorrami MH, Hossein Izadpanahi M et al. *Bladder Involvement in Behçet's Disease*. Vol 9.; 2012. <https://pdfs.semanticscholar.org/27fd/f3dbf6b43d6faf0ab281682ee8a4c1291824.pdf>. Accessed July 2, 2019.
6. Na SY, Shin J, Lee ES. Morbidity of solid cancer in Behçet's disease: Analysis of 11 cases in a series of 506 patients. *Yonsei Med J*. 2013;54(4):895-901. doi:10.3349/ymj.2013.54.4.895.
7. Dincer M, Cakir OO, Fikri O, Kandirali E. Bladder Dysfunction in Behçet's Disease. *J Acad Res Med*. 2016;7(2):86-88. doi:10.5152/jarem.2016.972.
8. Akpolat T, Akkoyunlu M, Akpolat I, Dilek M, Odabas AR, Ozen S. Renal Behçet's disease: A cumulative analysis. *Semin Arthritis Rheum*. 2002;31(5):317-337. <http://www.ncbi.nlm.nih.gov/pubmed/11965596>. Accessed July 3, 2019.
9. Ghosh S, Kumar M, Kumari P, Gadpayle AK. Acquired urethral meatal stenosis: A rare sequel of an aggressive form of Behçet's disease. *BMJ Case Rep*. 2013;2013. doi:10.1136/bcr-2013-009344.
10. Hatemi G, Christensen R, Bang D et al. 2018 update of the EULAR recommendations for the management of Behçet's syndrome. *Ann Rheum Dis*. 2018;77(6):808-818. doi:10.1136/ANNRHEUMDIS-2018-213225.
11. Tursten U, Gurler A, Boyvat A. Evaluation of clinical findings according to sex in 2313 Turkish patients with Behçet's disease. In: *International Journal of Dermatology*. Vol 42. ; 2003:346-351. doi:10.1046/j.1365-4362.2003.01741.x.